



TANTIA UNIVERSITY JOURNAL OF HOMOEOPATHY AND MEDICAL SCIENCE

www.tjhms.com

CASE STUDY

ROLE OF INDIVIDUALISED HOMOEOPATHIC MEDICINE IN THE TREATMENT OF PSORIASIS: A CASE STUDY

Dileep Kumar Sonkar¹, Neeraj Gandhi², Ratnesh Kumar³

¹Principal, State National Homoeopathic Medical College and Hospital, Lucknow, Uttar Pradesh, India

²Lecturer, State National Homoeopathic Medical College and Hospital, Lucknow

³Medical Officer, Govt. of Uttar Pradesh, SHD Kutub Nagar, Sitapur

Abstract

Received- 15/08/2023
Revised- 25/09/2023
Accepted- 30/09/2023

Key Word- Psoriasis,
PASI Score,
Homoeopathy,
Individualised medicine

Corresponding Author:-
Dileep Kumar Sonkar,
Principal, State National
Homoeopathic Medical
College and Hospital,
Lucknow, Uttar Pradesh,
India

Background: Psoriasis is a, chronic, disfiguring, inflammatory and proliferative condition of the skin, in which both genetic and environmental influences have a critical role.

Aims To assess the role of indicated homoeopathic simillimum in treatment of psoriasis. **Material and methods:**

Patient suffering from Psoriasis were treated in the OPD of State National Homoeopathic Medical College & Hospital, Lucknow. Analysis & evaluation of symptoms of the case was done after case taking. Patient was prescribed using homoeopathic principles; cases were then assessed with PASI Score at time of enrolment and every month. At the end conclusion was drawn on the basis of change in PASI score.

Descriptive Statistics was used for making inference. **Result :** Homoeopathic treatment reduced the PASI score of the patients suggesting utility of homoeopathy in treatment of

homoeopathy **Conclusion** : Homoeopathic similimum in treatment was encouraging , In Future randomized controlled study with larger sample may be undertaken for validation of results

INTRODUCTION

Psoriasis is a chronic dermatosis characterized by an unpredictable course of remission and relapses and presence at typical site of well defined erythematous papules and plaques, which are surmounted with large, silvery loose scales. There is frequent nail and joint involvement ^[1]. Psoriasis is a chronic relapsing disease of skin characterized by variable clinical features. The cutaneous lesions are usually so distinct that a clinical diagnosis is easy to make ^[2].

It is a common disease constituting 3-4% of all dermatological cases, but there is owing more tendency to reoccur, than actual new cases. It shows systemic origin by occurring symmetrically and its probable connection with some internal derangement by beginning on surface where the circulation is less active, namely the extensor surfaces, of all cases there is some hereditary evidence.^[3]

Psoriasis ravages the quality of life (QOL) of afflicted individuals. It is a disease with profound impact on the psychological and social aspect of the patient, particularly because of its

visibility. Thus assessment by a health professional of the extent of apparent disease in terms of the clinical severity alone may not suffice and a more holistic approach to the quality of life is mandatory^[4].

CASE REPORT

A 30- year old married Hindu male patient came to OPD (vide Reg. no. 12690, dated 10.02.20) of State National Homoeopathic Medical College & Hospital, Lucknow. He consulted us for the complaints of dry, itchy, white scaly skin eruptions started from face, spread to abdomen, scalp, arms and legs (within 2 months).Intense itching < closed room, from the warmth of bed, during perspiration, >in open air and on applying coconut oil.

Physical Generals: Dark complexioned, dry skin, tendency to recurrent boils which suppurated easily. Hot patient. Appetite-normal. Thirst – increased. Mouth- gum inflamed, odor offensive, stammering speech. Tongue- dry, white coated tongue with imprints of teeth. Desires -cheese, oily, spicy & salty food which caused eructation. Aversion warm drinks. Stool-

regular, 1-2times/24hrs. Perspiration – profuse, offensive, staining yellow. Sleep –sound, refreshing, mostly lying on left side. Dreams –frightful, snakes and about daily routine activities.

Mental Symptoms: Obstinate, sadness due to bitter experience, irritable, quarrelsome, whimsical, revengeful (as narrated by accompanying person). Abrupt but cared for social position, mania for work, sensitive and responsible. He was anxious about his family and business matters. Extrovert, talked loudly. Contradiction and interruption intolerant. He was disappointed with his relatives and suppressed his anger, reproached himself. He had anxiety in stuffy crowded place.

Personal history: Married, milkman and cheese seller.

Past history: Typhoid in Oct. 2019, fracture of left index finger; epistaxis in summer

Family history: Father: filariasis. Mother: hypertension.

Thermal Reaction: Hot

On General Examination: Auspitz sign positive

Provisional diagnosis: Psoriasis; based on Psoriasis Area and Severity Index (PASI) score which was 37.2

Miasmatic Diagnosis: Psoro- Sycotic

Totality of symptoms

- Obstinate;

- Marked irritability;
- Capriciousness;
- Bitter sadness
- Speech stammering;
- Perspiration - aggravates symptoms;
- Dreams –Frightful;
- Skin eruptions- psoriasis.
- Inflamed gum

Repertorial totality

- MIND – IRRITABILITY
- MIND- OBSTINATE
- MIND- CAPRICIOUSNESS
- MIND – SADNESS - bitter
- MOUTH – SPEECH- stammering
- MOUTH – INFLAMMATION – Gums
- PERSPIRATION –SYMPTOMS- agg- during perspiration
- DREAMS – FRIGHTFUL
- SKIN- ERRUPTIONS- psoriasis

Repertorisation

Repertorisation was done following Synthesis 9.0 (English) repertory (using RADAR 10.0 software)⁵

	ars.	merc	sep.	sulph.	phos.	cham.	nu-v.	bell.	ait.	l/c	ruis.	acrt.	calc.
1. MIND - IRRITABILITY (570) 1	8	8	8	8	7	7	7	7	7	7	7	7	7
2. MIND - SADNESS - bitter (2) 1	17	17	17	16	18	16	15	15	14	13	12	12	1
3. MIND - CAPRICIOUSNESS (148) 1													
4. MIND - OBSTINATE (142) 1													
5. MOUTH - SPEECH - stammering (90) 1													
6. PERSPIRATION - SYMPTOMS - agg. - du... (41) 1													
7. MOUTH - INFLAMMATION - Gums (66) 1													
8. SKIN - ERUPTIONS - psoriasis (102) 1													
9. DREAMS - FRIGHTFUL (245) 1													

Fig. 1: Repertorisation⁵

Table 1: Repertorial analysis⁵

Name of medicine	No. of rubrics covered	Total marks obtained
<i>Mercurious solubilis</i>	8	17
<i>Arsenic Album</i>	8	17
<i>Sulphur</i>	8	17
<i>Chamomilla</i>	7	18

Prescription: On 7.01.2020, *Chamomilla* 30, 3 doses at 10 minutes interval along with Placebo, BD was prescribed for 15

days on the basis of repertorial analysis and in consultation with *Materia Medica*^{6,7,8} on following features hot patient irritable, intolerant when interrupted, aversion to warm drinks and thirst increased and repertorial totality also covers this medicine in high grade. Potency 30 was selected because emphasis on physical symptoms was also given apart from mental symptoms. He was advised to apply coconut oil on eruptions regularly.

Table 2: Follow-up

Date	Symptom	Prescription
18.02.2020	Slight reduction in itching and redness. Gums regained normal texture. PASI score- 24.2	Placebo BD for 15 days
17.03.2020	Marked improvement in itching, redness, thickness and scaling. Stammering also better. PASI score- 4.1	After 18/02/2020, Placebo, BD was prescribed for 15 days.
29.04.2020	New eruptions appeared. PASI score- 5.4	After 17/03/2020, Placebo, BD was prescribed for 15 days. On 29/04/20 <i>Calcarea sulphuricum</i> 30, 1 dose was given along with Placebo BD for 15 days based on repertorial chart in which calc sulph covered all mental symptom and it also bears characteristics of <i>Calcarea carbonicum</i> and <i>Sulphur</i> , so Hot remedy of <i>Calcarea</i> was chosen for prescription.
09.05.2020	Eruptions disappeared. Mental and general condition improved.	Placebo BD for 15 days

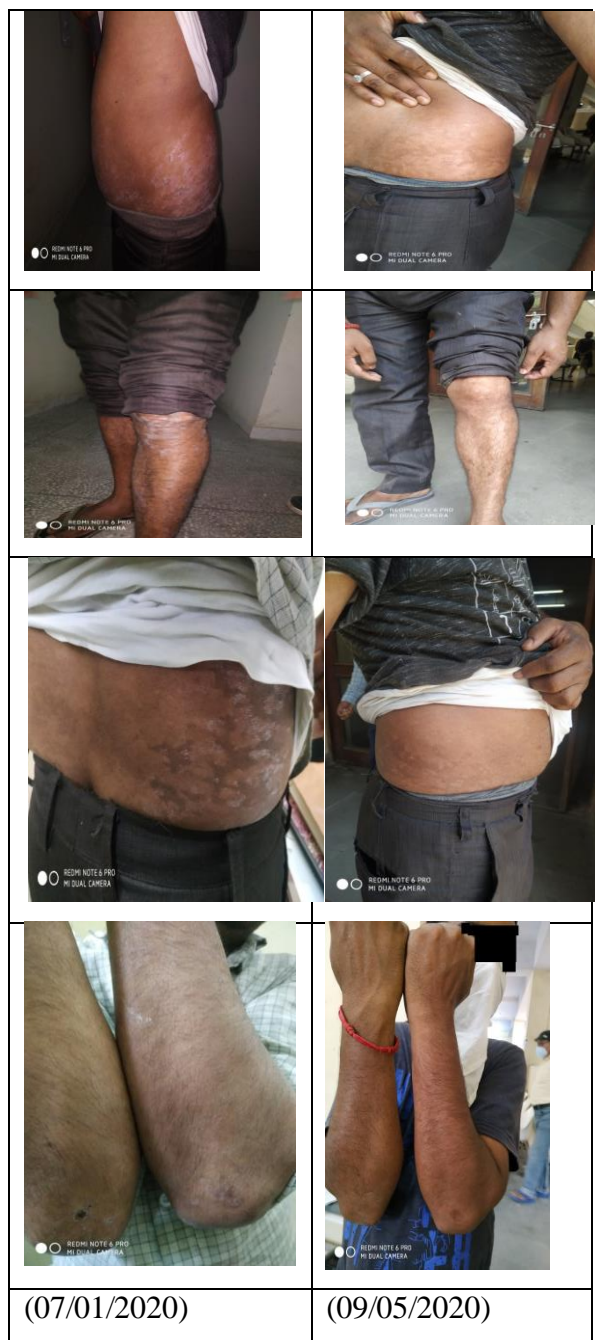

Fig. 2: Before and after treatment of Case

CONCLUSION

As evident from before and after treatment pictures and PASI scores, homoeopathic medicines yielded promising results in the treatment of patients suffering from Psoriasis in which indicated homoeopathic *similimum* had acted.

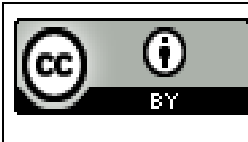
REFERENCES

1. Khanna, N., Illustrated Synopsis of Dermatology and Sexually Transmitted Diseases, Elsevier. 4th Edition 2013, p 40-50.
2. Michael P, Schon W, Boehncke H. Psoriasis. New Eng J Med 2005; 352: 1899- 912.
3. Javidi Z, Meibodi NT, Nahidi Y. Serum lipid abnormalities and psoriasis. Indian J Dermatology 2007; 52: 89-92
4. Dearborn M Frederick, Disease of The Skin (including exanthemata), reprint edition 2006, New Delhi, B. Jain publishers (p) ltd. Pp.124.
5. Baker H. Psoriasis a review. Dermatologica 1975; 150: 16-25.
6. RADAR[computer program]. Version 10.0. Belgium: Archibel.2009.
7. Boericke William. Pocket Manual of Homoeopathic Materia Medica. 9th ed. New Delhi: B. Jain Publishers(P)Ltd.; 1985.
8. Allen TF. Encyclopedia of Pure Materia Medica. New Delhi: B. Jain Publishers(P)Ltd.; 2009.
9. Kent JT. Lectures on Materia Medica. New Delhi: B. Jain Publishers(P)Ltd.; 1989.

How to Cite this Article- Sonkar D. K., Gandhi N., Kumar R., Role Of Individualised Homoeopathic Medicine In The Treatment Of Psoriasis: A Case Study. TUJ. Homo & Medi. Sci. 2023;6(3):90-95.

Conflict of Interest: None

Source of Support: Nil



This work is licensed under a Creative Commons Attribution 4.0 International License

